

# “Watch Out! Pneumonia Secondary to *Achromobacter Denitrificans*”

Aundhakar SC, Mane MB, Bharadiya AA, Pawar SK<sup>1</sup>

Departments of Medicine and <sup>1</sup>Microbiology, Krishna Institute of Medical Sciences and Research Centre, Karad, Maharashtra, India

**Address for correspondence:**

Dr. Amit A Bharadiya,  
Room No. 102, I.H.R Hostel, Krishna  
Institute of Medical Sciences,  
Karad - 415 110, Maharashtra, India.  
E-mail: dr.apple4u@yahoo.co.in

## Abstract

Pneumonia is the cause of significant morbidity and mortality especially in developing countries. The frequency and importance of emerging new pathogens have significant implications for therapy. We report a case of pneumonia caused by a very rare organism, *Achromobacter denitrificans* which was treated successfully with intravenous meropenem injections for 14 days. Review of available literature has documentation of isolation of *Achromobacter xylosoxidans* from endotracheal aspirate culture but this is probably the first case of pneumonia due to *A. denitrificans*.

**Keywords:** *Achromobacter denitrificans*, *Achromobacter* species, Pneumonia

## Introduction

The list of possible etiologic agents for community acquired pneumonia, hospital acquired pneumonia and health care-associated pneumonia is extensive as well as expanding. Newly identified pathogens include *Hantaviruses*, *Metapneumoviruses*, the *Coronavirus* responsible for severe acute respiratory syndrome and community-acquired strains of methicillin-resistant *Staphylococcus aureus*. The frequency and importance of emerging new pathogens have significant implications for therapy. *Achromobacter denitrificans* is one such newly found bacteria causing pneumonia in our patient and has not been reported anywhere yet.

## Case Report

The present case report is about a 48-year-old male patient, working as a clerk in a chemical factory, was brought to our hospital with the complaints of fever, breathlessness and cough with expectoration since 7 days. Fever was moderate, continuous in nature without any chills or rigors. Breathlessness was gradual in onset and progressive in nature. Cough was productive; the sputum was yellowish green in

color and around 30 ml/day with occasional hemoptysis. There was no history of any recent weight loss, loss of appetite, burning micturition, chest pain, swelling of lower limbs, orthopnea or paroxysmal nocturnal dyspnea. He had suffered from pulmonary tuberculosis 12 years ago in 2001 and had taken complete treatment for it.

On general examination, patient was conscious, well-oriented and poorly built. He had a pulse rate of 108/min, blood pressure of 100/60 mmHg, respiratory rate of 28 cycles/min. Room air oxygen saturation was around 95%. There was no pallor, icterus, clubbing, cyanosis, lymphadenopathy or peripheral edema. Jugular venous pulsations were normal.

On systemic examination, patient had reduced breath sounds in right upper suprascapular, interscapular and infraclavicular region with coarse crepitations bilaterally. Rest systemic examination was normal.

Hemogram revealed a total leucocyte count of 13,200/cumm with 86% polymorphs and 14% lymphocytes. His erythrocyte sedimentation rate was 120 and he was seronegative. Chest X-ray [Figure 1] showed bilateral fibro infiltrative Koch's with cavities in right upper lobe. There was volume loss of the right lung and mediastinal shift to right. Computed tomography-thorax [Figure 2, 3 and 4] was suggestive of features of old pulmonary Koch's with residual bilateral bronchiectasis and secondary infection. There was no evidence of any malignancy. Sputum examination was negative for acid fast bacilli. Sputum cultures carried out with the help of calorimetric VITEK-2 card identified *A. denitrificans*, repeatedly on two samples without any

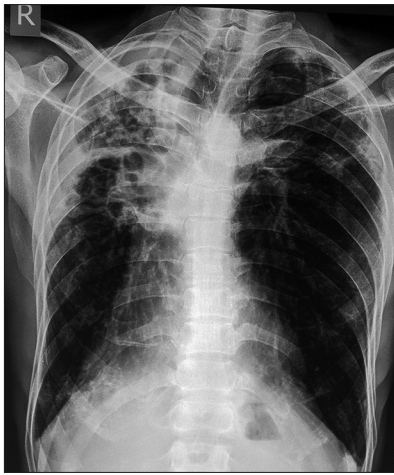
Access this article online

Quick Response Code:

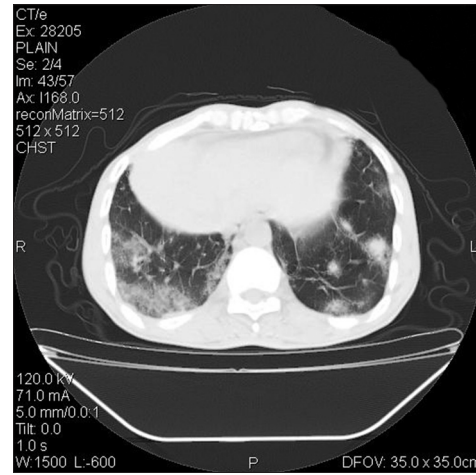


Website: [www.amhsr.org](http://www.amhsr.org)

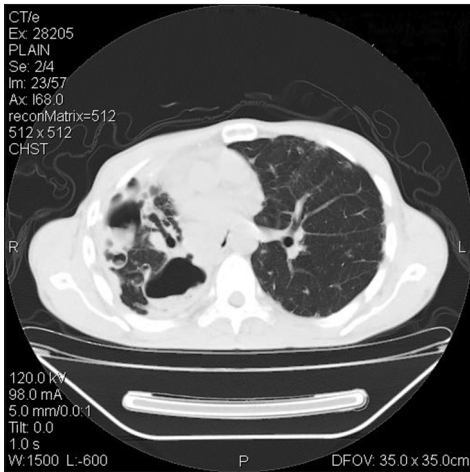DOI:  
10.4103/2141-9248.131700



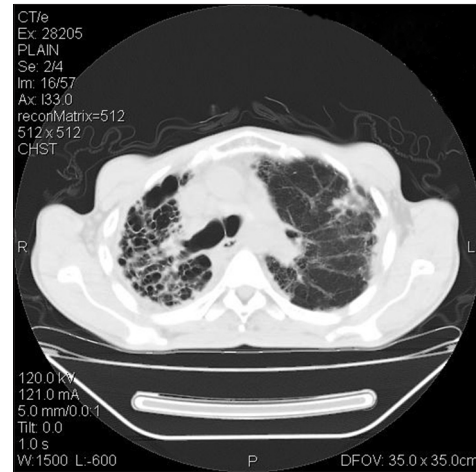**Figure 1:** Chest X-ray posteroanterior view: Right upper lobe pulmonary fibrosis and tracheal shift to the right side with secondary infection



**Figure 2:** Computed tomography-chest: Bilateral consolidation (right more than left), secondary infection, pleural thickening



**Figure 3:** Computed tomography-chest: Right lung fibrosis and volume loss



**Figure 4:** Computed tomography-chest: Right lung bronchiectasis

concurrent infection. It was sensitive to meropenem, imipenem, piperacillin, ticarcillin, trimethoprim-sulfamethoxazole and third generation cephalosporins. It was resistant to all the aminoglycosides, fluoroquinolones, tetracycline and first and second generation cephalosporins. Blood cultures were sterile. Coagulation profile, renal functions, liver functions, electrolytes were within the normal limits.

Injection meropenem 1 g intravenously every 8 h was started. He showed symptomatic improvement after 1 week. His sputum culture after 7 days detected the same bacteria. Meropenem was continued until 14 days. Sputum culture repeated 14 days after starting meropenem did not detect growth of any pathogen.

## Discussion

*A. denitrificans* is a species that belongs to the genus achromobacter. It is a Gram negative, mobile, strictly aerobic, ubiquitous bacterium not fermenting glucose, oxidase and

catalase positive. It inhabits soil and aquatic environments, including well water, intravenous fluids and water in humidifiers.<sup>[1]</sup> It has been isolated from renal abscess.<sup>[2]</sup>

*A. xylosoxidans*, the other sub-species of genus achromobacter is more commonly isolated in adults with comorbidities or indwelling medical devices. The symptomatic infections include natural/prosthetic valve endocarditis, meningitis, pneumonia, conjunctivitis, osteomyelitis, peritonitis and intra-abdominal abscess.<sup>[3]</sup> Polymicrobial infections have been commonly seen in patients infected by *A. xylosoxidans*. Most common concomitant infecting organisms were *Acinetobacter* species, *Pseudomonas* species and *Staphylococcus* species.<sup>[4]</sup>

Treatment of achromobacter pneumonia depends upon the susceptibility tests. Most achromobacter species isolates have been found to be resistant to first and second-generation cephalosporins, aminoglycosides and narrow-spectrum penicillins; susceptible to sulfonamides, carbapenems, broad-spectrum penicillins, third-generation cephalosporins; and variably susceptible to fluoroquinolones.<sup>[5]</sup>

*A. xylosoxidans* pneumonia has been associated with a high case-fatality rate of 67%.<sup>[4]</sup> Complications include empyema, adult respiratory distress syndrome, chronic scarring and secondary and recurrent pneumonia.<sup>[4]</sup> Our case had no complications.

## Conclusion

Our patient had *A. denitrificans* pneumonia and it was treated successfully with meropenem. Rising incidence of achromobacter infections in human beings needs further active research.

## References

1. Spear JB, Fuhrer J, Kirby BD. *Achromobacter xylosoxidans* (*Alcaligenes xylosoxidans* subsp. *xylosoxidans*) bacteremia associated with a well-water source: Case report and review of the literature. *J Clin Microbiol* 1988;26:598-9.
2. Sgrelli A, Mencacci A, Fiorio M, Orlandi C, Baldelli F, De Socio GV. *Achromobacter denitrificans* renal abscess. *New Microbiol* 2012;35:245-7.
3. Teng SO, Ou TY, Hsieh YC, Lee WC, Lin YC, Lee WS. Complicated intra-abdominal infection caused by extended drug-resistant *Achromobacter xylosoxidans*. *J Microbiol Immunol Infect* 2009;42:176-80.
4. Duggan JM, Goldstein SJ, Chenoweth CE, Kauffman CA, Bradley SF. *Achromobacter xylosoxidans* bacteremia: Report of four cases and review of the literature. *Clin Infect Dis* 1996;23:569-76.
5. Rolston KV, Messer M. The *in-vitro* susceptibility of *Alcaligenes denitrificans* subsp. *xylosoxidans* to 40 antimicrobial agents. *J Antimicrob Chemother* 1990;26:857-60.

**How to cite this article:** Aundhakar SC, Mane MB, Bharadiya AA, Pawar SK. "Watch out! Pneumonia secondary to *Achromobacter denitrificans*". *Ann Med Health Sci Res* 2014;4:22-4.

**Source of Support:** Nil. **Conflict of Interest:** None declared.